

## Important role of gemcitabine in the treatment of classic Kaposi's sarcoma

Fable Zustovich, Giuseppe Lombardi, and Davide Pastorelli

*Oncologia Medica 1, Istituto Oncologico Veneto, IRCCS, Padua, Italy*

Kaposi's sarcoma (KS) is a rare multifocal lympho-angioproliferative disease related to human herpesvirus 8. Classic KS affects mainly elderly men and early stage treatment is localized with radiotherapy and intralesional vinca alkaloids, while for some aggressive KS variants chemotherapy is needed. To date, various antiproliferative drugs including interferon- $\alpha$ , vinblastine, bleomycin, dacarbazine, anthracyclines, and paclitaxel have been studied with an overall response rate of up to 80%<sup>1</sup>. Gemcitabine is widely used in oncology practice and has a good toxicity profile; it is therefore often included in chemotherapy combinations and used as a single agent in the elderly.

We report the case of a 74-year-old man with a diagnosis of classic KS of the lower limbs, who came to our observation with disease progression. KS lesions involved the upper and lower limbs with subcutaneous dissemination to the left thigh accompanied by conspicuous edema (Figures 1 and 2). The patient was heavily pretreated with local radiotherapy, interferon- $\alpha$  and multiple lines of chemotherapy including vinblastine, pegylated liposomal doxorubicin, and paclitaxel. We started treatment with gemcitabine at a fixed infusion rate (FIR) of 10 mg/m<sup>2</sup>/minute on days 1, 8 and 15 every 28 days. The clinical pattern of the lower limbs and left thigh improved dramatically after the first gemcitabine administration and the improvement was confirmed after the end of chemotherapy for a total of 6 courses (Figures 1 and 2). The patient then entered a follow-up program and has been well and without disease progression up to now, 14 months after treatment.

The present case showed a marked and long-lasting response in a patient with heavily pretreated progressive classic KS, using single-agent gemcitabine chemotherapy without any important side effects. A review of the literature worldwide included only one previous report with gemcitabine for the treatment of KS. Brambilla *et al.*<sup>2</sup> administered gemcitabine with a standard schedule of 1200 mg/m<sup>2</sup> over a hypothetical 30-minute infusion (the duration of infusion was not reported in the paper) on days 1 and 8 every 3 weeks to 11 patients with refractory classic KS. The authors obtained an overall response rate of 100% with 1 complete response and 10 partial responses.

We administered gemcitabine at a fixed infusion rate. Prolonged infusion (more than 30 minutes) increased the intracellular rate of gemcitabine's active metabolites, thereby enhancing the therapeutic and toxic effects<sup>3</sup>. Our previous experience in lung cancer patients has shown that gemcitabine doses of up to 1200 mg/m<sup>2</sup> infused in 120 minutes on days 1, 8 and 15 every 4 weeks are safe<sup>4</sup>. Two phase II randomized clinical trials evaluated the efficacy of FIR administration of gemcitabine *versus* the standard 30-minute infusion schedule in non-small cell lung cancer and pancreatic cancer patients. Both studies showed a favorable trend for the FIR modality<sup>5,6</sup>.

Moreover, gemcitabine does not affect the lymphocyte immunoreactive activity in patients with solid tumors and seems to be synergistic with immunotherapy in animal models<sup>7</sup>. Thus, its combination with interferon- $\alpha$  and/or interleukin-2 should be investigated. In conclusion, our findings and the previous findings of Brambilla support the efficacy and safety of gemcitabine in refractory and progressive KS, especially in elderly patients. FIR administration should be preferred and combination with immunotherapy should also be considered.

**Key words:** Kaposi's sarcoma, gemcitabine, elderly patient, oncology, chemotherapy.

Correspondence to: Dr Fable Zustovich, Oncologia Medica 1, Ospedale Busonera, Via Gattamelata 64, 35128 Padova, Italy.

Mobile +39-347-9775504;  
fax +39-049-8042089;  
e-mail fable.zustovich@ioveneto.it

Received December 12, 2008;  
accepted January 13, 2009.

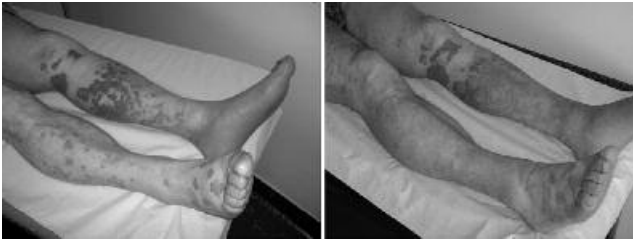

Figure 1 - Cutaneous pattern of the leg before (left) and after (right) gemcitabine treatment.

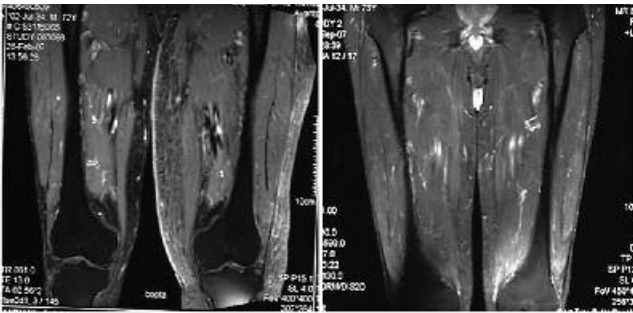


Figure 2 - MRI with contrast pattern of the left thigh before (left) and after (right) gemcitabine treatment.

## References

1. Gottlieb JJ, Washenik K, Chachoua A, Friedman-Kien A: Treatment of classic Kaposi's sarcoma with liposomal encapsulated doxorubicin. *Lancet*, 350: 1363-1364, 1997.
2. Brambilla L, Labianca R, Ferrucci SM, Taglioni M, Barreschi V: Treatment of classical Kaposi's sarcoma with gemcitabine. *Dermatology*, 202: 119-122, 2001.
3. Grunewald R, Abbruzzese JL, Tarassoff P, Plunkett W: Saturation of 2',2'- difluorodeoxycytidine 5'-triphosphate accumulation by mononuclear cells during a phase I trial of gemcitabine. *Cancer Chemother Pharmacol*, 27: 258-262, 1991.
4. Cartei G, Binato S, Trestin AR, Ceravolo R, Salmaso F, Pastorelli D, Zustovich F, Paganelli F, Mattiazzi M, Vattei E: Phase II trial of gemcitabine as prolonged infusion in metastatic non-small-cell lung cancer. *Lung Cancer*, 41 (Suppl 2) s229: 545 (abstract), 2003.
5. Ceribelli A, Gridelli C, De Marinis F, Fabi A, Gamucci T, Cortesi E, Barduagni M, Antimi M, Maione P, Migliorino MR, Giannarelli D, Cognetti F: Prolonged gemcitabine infusion in advanced non-small cell lung carcinoma: a randomized phase II study of two different schedules in combination with cisplatin. *Cancer*, 98: 337-343, 2003.
6. Tempero M, Plunkett W, Ruiz Van Haperen V, Hainsworth J, Hochster H, Lenzi R, Abbruzzese J: Randomized phase II comparison of dose-intense gemcitabine: thirty-minute infusion and fixed dose rate infusion in patients with pancreatic adenocarcinoma. *J Clin Oncol*, 21: 3402-3408, 2003.
7. Nowak AK, Robinson BW, Lake RA: Synergy between chemotherapy and immunotherapy in the treatment of established murine solid tumors. *Cancer Res*, 63: 4490-4496, 2003.